Application of Advanced Dressings in the Treatment of Stevens-Johnson Syndrome in a Pediatric Patient

SGAWCM 2025 Experience
May 28th-30th Hybrid
São Paulo Brazil
SOBRATAFE
Centro de Convenções Rebouças

Thais Brito Anastacio Figueiredo[1]; Aline de França Mangueira[2]; Arthur Vinícios Araújo De Souza[3].
[1]TBASAUDE
[2]Centro Universitário Estácio do Pantanal
[3]Universidade de Rio Verde, Campus Goiânia.

Objective:

To report the use of advanced technological dressings in the treatment of severe drug-induced dermatitis (Stevens-Johnson Syndrome) in a pediatric patient, focusing on their effectiveness in promoting healing, preventing secondary infections, and relieving pain.

Methods:

This is a descriptive case study involving a child admitted to the intensive care unit who developed skin lesions after an allergic reaction to an antibiotic (amikacin). After failure of conventional treatment, a new protocol was initiated. The intervention consisted of cleansing with 0.1% aqueous polyhexanide, application of polyhexanide gel as the primary dressing, rayon gauze soaked with tea tree and copaiba oils, and a cellulose membrane for lip lesions. Intact skin was moisturized with a lotion containing urea, D-panthenol, aloe vera, and vitamins A and E. Dressings were changed every 72 hours.

Figure 1

Figure 2

Figure 3

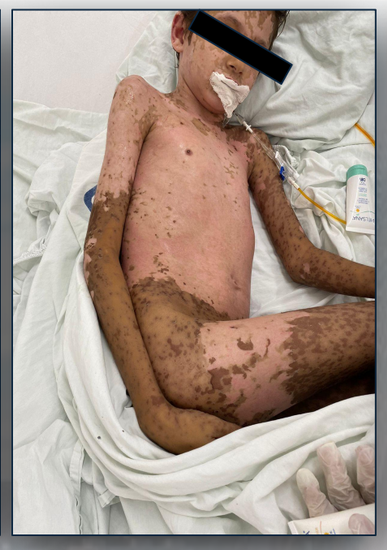

Figure 4

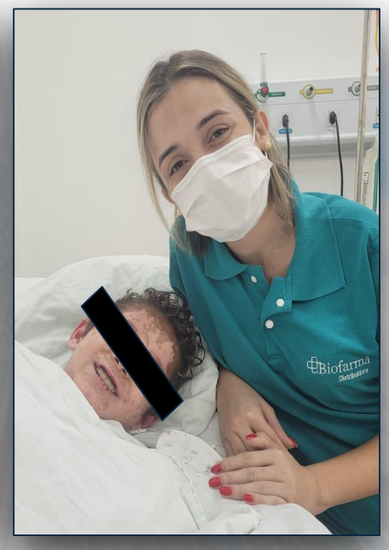

Figure 5

Figures 1 and 2 – Images taken prior to treatment, illustrating the extent of the lesion before wound care intervention.

Figure 3, 4 and 5 – Post-treatment image demonstrating marked improvement of the lesion following the wound care protocol.

Results:

Stevens-Johnson Syndrome, being a rare and severe condition, requires a careful and specialized approach. In this context, systematizing lesion assessment through standardized protocols becomes essential to ensure safe, effective, and humanized care. The protocol followed these steps: (1) initial assessment of the lesion; (2) documentation of the lesion's characteristics (location, depth, exudate, odor, pain, edges); (3) classification of the healing stage and suspicion of infection; (4) automated suggestion of conduct and appropriate dressing; and (5) space for additional observations by the healthcare team.

The choice of dressings prioritized technologies that were infection-preventive, atraumatic, and promoted healing. Rapid clinical improvement was observed during treatment. The lesions progressed to the proliferative phase, with well-vascularized tissue, absence of odor and infection, and reduced pain during dressing changes. By the seventh day, the lesions were epithelialized, and the skin showed signs of cellular renewal.

The experience revealed that adopting a systematic protocol contributed to organized care, facilitated communication among professionals, and improved the team's perception of the safety of the adopted approach. The absence of infectious complications and rapid epithelialization reinforce the clinical effectiveness of the management applied. Future studies may evaluate the impact of such protocols.

Conclusion:

The use of polyhexanide, cellulose membrane, and essential oil-based dressings proved effective in accelerating wound healing, reducing trauma and discomfort, controlling odors, and maintaining the integrity of perilesional skin. Advanced dressings have shown to be a safe and effective therapeutic option in the management of severe drug-induced dermatological reactions in pediatric patients.

E-mail: tbasaude18@gmail.com

I have no conflict of interest.

Protected by Copyright – Reproduction Prohibited